The Australian and New Zealand College of Veterinary Scientists

Building 3, Garden City Office Park
2404 Logan Road
EIGHT MILE PLAINS QLD 4113

Telephone: (07) 3423 2016
Email: marketing@anzcvs.org.au
Web: anzcvs.org.au

ONLINE SCIENTIFIC SERIES 2020

ONLINE ABSTRACT FORUM PROCEEDINGS

TABLE OF CONTENTS

SURGERY CHAPTER SCIENTIFIC ABSTRACTS

Association of liver mass location and surgical morbidity and mortality

Dr Vaughan Moore[1]

[1]*Small Animal Specialist Hospital, Sydney, Australia*

Right-sided liver lobectomies are reported to have a poorer prognosis with intraoperative mortality up to 40%.[1,2,3] A retrospective case series designed to evaluate the relationship between solitary liver mass location and the morbidity and mortality associated with its surgical resection in dogs was performed (2008-2020).

Potential predictors of morbidity and mortality included age, sex, weight, location and size of mass, degree of hepatic resection (partial or complete), mode of resection (TA stapler, hilar dissection or other), number of lobes excised, incision extension to the thorax, surgeon (specialist or resident) and histopathological diagnosis. Descriptive data was stratified by mass location and compared (Fisher's exact [categorical], Kraskal-Wallis [continuous data]). The association between mass location and morbidity and mortality was evaluated using separate multivariate logistic regression models.

One hundred and twenty-one (66 female, 55 male) dogs were included (median age 11; Q1-Q3 9.8 to 12.7 years). Liver masses were in the left (71 dogs), central (34 dogs) and right (16 dogs) divisions. Post-operative complications occurred in 35 dogs (29%) while seven dogs (5.7%) died. Resection of right divisional masses, compared to left and central, was more likely to require thoracic incision ($p = 0.008$). There were no significant predictors of mortality. Age (OR 1.3, $p = 0.03$, CI 1.03 - 1.6), thorax incision (OR 7.5, $p = 0.0002$, CI 2.6 - 23.3) and use of a TA stapler (OR 0.26, $p = 0.01$, CI 0.09 - 0.7) were significantly associated with morbidity.

Surgical resection of right divisional liver masses was not associated with increased morbidity or mortality.

References

1. Liptak JM, William SD, Monnet E et al. Massive hepatocellular carcinoma in dogs: 48 cases (1992-2002). JAVMA 2004;225:1225-1230.
2. Liptak JM. Cancer of the Gastrointestinal Tract, Section F Hepatobiliary Tumors. In: Withrow S, Vail DV editors. Withrow and MacEwen's Small Animal Clinical Oncology. 4th edn. Saunders, Missouri, 2007;488.
3. Williams TM, Culp RP, Cavanaugh EF et al. Alimentary Tract. In: Kudnig ST, Bernard S editors. Vet Surg Oncol. 1st edn. Wiley-Blackwell, Oxford, 2002;202.

Computed tomography and surgical findings of migrating grass seeds in dogs

Dr Tesheena Nash, Professor Giselle Hosgood[1]

[1]*The Animal Hospital at Murdoch University, Perth*

Migrating grass seeds cause discomfort for dogs due to associated soft tissue disruption and abscessation.

Records from 35 dogs undergoing computed tomography (CT) and surgery to explore sites of suspected migrating grass seeds from 2013-2020 were reviewed. Frequent clinical signs for presentation were recurring mass/es (11/35), non-healing wound/s (10/35) and respiratory compromise (4/35). The most common site of abscessation was within subcutaneous tissues (17/35). Characteristic CT findings included soft tissue thickening, fibrosis, oedema, pocketing containing visible fluid and regional lymphadenomegaly. Foreign material was identified on 7/35 CT studies. Nine dogs demonstrated evidence of soft tissue tracking between at least two body regions. The sensitivity of CT in identifying reactive soft tissue change was 100%. Surgical exploration was directed to the focal site identified on CT and resulted in positive identification of foreign matter in 21/35 dogs. Common changes noted at the time of surgery were soft tissue thickening or necrosis, steatitis and/or a soft tissue tract. The most frequent organism cultured from tissue samples was *Pasturella canis* (7/19 positive cultures). All dogs survived to discharge, and the median time to return to normal function post-operatively was 14 days. Three dogs required repeat CT and exploratory surgery to recover further foreign material. Long term outcome was excellent for all dogs.

Migrating grass seeds pose a significant surgical challenge in locating the focal area of affected tissue. CT is a valuable diagnostic modality to pinpoint the location and extent of the lesion and direct surgical exploration.

Intra-articular methylprednisolone and bupivacaine treatment of sesamoiditis in dogs

Dr Craig Thomson[1]

[1]*North Coast Veterinary Specialists, Tanawha, Australia*

Sesamoiditis is a disease of the paired sesamoid bones. Conservative management consisting of restricted activity or splinting of the digits is the current treatment recommendation for patients with sesamoid disease.[1] Anecdotally the response to therapy involves gradual improvement in the level of lameness over the period of confinement.

A retrospective cohort study was used to investigate the effectiveness of intra-articular joint injection with methylprednisolone and bupivacaine (IMPB) into the metacarpophalangeal (MCP) and metatarsophalangeal (MTP) joints of affected digits for treatment of sesamoiditis, compared with conservative management. Outcomes measured were the speed and longevity of the response. Dogs were client-owned patients of North Coast Veterinary Specialists and Referral Hospital.

Fifty-eight dogs treated (IMPB) (1-3 injections) and 18 dogs conservatively managed between from 2015 to 2020 were included in the study.

In the IMPB group 52/58, (89.7%), demonstrated resolution of lameness within 1 week, compared with 0/18, (0%), conservatively managed cases, $?^2 = 51.1$, $p < 0.001$. At 6 months, resolution of lameness remained higher in the IMPB group (56/58, 96.5%) than in the conservative group (10/18, 55.6%), $?^2 = 20.2$, $p < 0.001$. Forty-nine patients (49/76,64.4%) had comorbidities, 41/58 (70.7%) in the IMPB group and 8/18 (44.4%) in the conservative group, p=0.12, which made diagnosis of sesamoiditis difficult. Intra-articular injection of the joints allowed subjective determination of the contribution of sesamoid disease.

Treatment of sesamoiditis using IMPB results in rapid relief of pain and lameness. Conservative management is effective in fewer dogs and takes longer to achieve resolution.

References

1. Mathews K, Koblik P, Whitehair J, Kass PH, Bradley C. Fragmented palmar metacarpophalangeal sesamoids in dogs: a long-term evaluation. Vet Comp Ortho Trauma 2001;14:7-14.

Urinary Catheterisation of female dogs – a comparison between three techniques for catheter placement

Dr Abbie Tipler[1], Adj Professor Philip Moses[1], Ms Eleanor Moses, Dr Ristan Greer, Dr Peter Delisser[1], Dr Blaine McCracken[2]

[1]Veterinary Specialist Services, Brisbane, Australia, [2]Western Australian Veterinary Emergency and Specialty, 1/640 Beeliar Drive, Success, WA 6164, Australia

The objective of this study was to describe a new technique for urinary catheterisation of female dogs using a novel catheterisation device and to compare the time taken to place a catheter using this technique with traditional techniques. A secondary objective was to survey participants on which of the techniques they preferred.

Female canine cadavers of varying sizes were utilised and veterinary students who had not previously placed a urinary catheter were enrolled. Each participant performed three catheterisation techniques; Visual with speculum (SPEC), Blind Palpation (BP) and catheterisation with Novel Catheterisation Device (NCD) on three sizes of dog. Time required using each technique was compared using Kaplan-Meier plots and mixed models Cox Proportional Hazards regression. Median times to catheterisation were 300s (IQR 261-417s) with the SPEC method, 420s (IQR 253-545s) with the NCD method, and 725s (574-1032s) with the BP method. Both SPEC and NCD methods were significantly faster compared to the BP method, with Hazard Ratios of 3.66 (95% CI 1.94-6.91, $P < 0.001$) and 3.57 (95% CI 1.87-6.81, $P<0.001$), respectively.

Six of 9 participants found the novel catheterisation device the easiest technique, 5/9 of the participants found the palpation technique most difficult and 4/9 found the speculum technique most difficult. BP appears to be the technique of least preference and increased time requirement. The novel urinary catheterisation device may provide a simpler method of visualisation of the urethral papilla and may provide a more sterile way of placing the catheter, although further investigation is needed to confirm this.

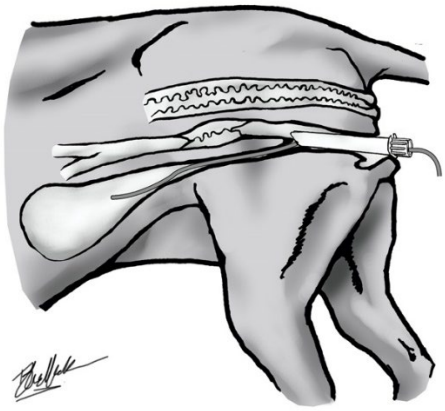

Diagram showing the catheterisation device inserted into the vulva with the longer dorsal edge blocking the vagina, therefore allowing placement of a urinary catheter through the centre.

CONTACT US

Telephone: (07) 3423 2016
Email: marketing@anzcvs.org.au
Web: anzcvs.org.au